

Acute Myelofibrosis and Malignant Hypercalcemia

JOSEPH A. LIBNOCH, M.D.
KAMEL AJLOUNI, M.D.*
WILLIAM L. MILLMAN, M.D.
ALEJANDRO R. GUANSING, M.D.
GEORGE B. THEIL, M.D.
Milwaukee, Wisconsin

A 33 year old man presented with symptoms of one week's duration; he had a serum calcium of 22.5 mg/dl and a markedly hypercellular bone marrow. Despite therapy with saline diuresis, furosemide, mithramycin, total parathyroidectomy and corticosteroids, symptomatic hypercalcemia was poorly controlled. Inappropriate serum parathyroid hormone (PTH) levels were found before and after parathyroidectomy whereas assays of the peripheral blood for osteoclast-activating factor and prostaglandin E (PGE₂) were negative. An elevated leukocyte alkaline phosphate level, the inability to aspirate marrow, the marked generalized hyperplasia of all hematopoietic marrow elements, the focal accumulations of blastic cells and increasing reticulin fiber formation led to the diagnosis of acute myelofibrosis. A single course of cytosine arabinoside and thioguanine therapy was followed by profound hyperphosphatemia, hypocalcemia and death. The rarity of hypercalcemia with myeloproliferative disorders is documented by a review of the world literature, and the possible mechanism for hypercalcemia in this patient is discussed.

Our purpose here is to describe a young man who presented with severe hypercalcemia as the first manifestation of an unusually acute and uncommon myeloproliferative disorder.

CASE REPORT

A 33 year old Puerto Rican man was in excellent health until 10 days before his admission when he began to experience fatigue and dull, nonradiating bilateral chest and upper abdominal pain; the pain was gradual in onset and was followed some days later by nausea, vomiting, polyuria, polydipsia and nocturia. He denied use of medications or exposure to toxic substances, and his past and family history were noncontributory.

On admission he appeared acutely ill and lethargic, and he was nauseated and groaning with discomfort. Vital signs were normal and the physical examination disclosed no abnormalities except for diffuse abdominal tenderness. Lymph nodes, liver and spleen were not palpable.

Laboratory data on admission included urinalysis, complete blood count, platelet count, serum sodium, potassium, carbon dioxide, blood urea nitrogen, glucose and amylase levels. X-ray films of the chest and abdomen were within normal limits.

By the next morning the patient was semicomatose, areflexic and without bowel sounds. The blood calcium and phosphate samples drawn the previous day demonstrated respective values of 14.7 and 4.3 mg/dl and when redrawn revealed levels of 22.5 and 3.8 mg/dl. A repeat serum amylase was again normal. An initial trial of rapid saline infusion resulted in no significant decrease of the calcium level and intravenously administered furosemide, up

From the Medical Service, Veterans Administration Center, Wood (Milwaukee), Wisconsin; and the Department of Medicine, Medical College of Wisconsin, Milwaukee, Wisconsin. This study was supported in part by Veterans Administration Research Project No. 8350-01. Requests for reprints should be addressed to Dr. Joseph A. Libnoch, Veterans Administration Center, Wood, Wisconsin 53193. Manuscript accepted March 5, 1976.

* Present address: University of Jordan School of Medicine, Amman, Jordan.

to 80 mg/hour, was added. Despite the marked increase in urinary excretion of calcium (2,332 mg in 7.35 liters over a 12 hour period), the serum calcium level failed to fall below 17 mg/dl and the blood urea nitrogen and creatinine levels began to rise (Figure 1). The administration of mithramycin as a single intravenous dose of 50 μ g/kg was followed by a fall in the serum calcium level to 7.9 mg/dl 48 hours later. Clinical improvement was rapid; the patient became alert and essentially asymptomatic, and physical findings became normal. The blood urea nitrogen returned to normal, but the creatinine level remained mildly elevated for the balance of his illness.

Serum and urine protein electrophoresis, roentgenographic studies including a skeletal survey, a series of the upper and lower gastrointestinal tract, oral cholecystogram and intravenous pyelography, and repeated complete blood counts, electrolytes and urinalysis were within normal limits. An elevation in the serum amylase level was noted which persisted during the remainder of hospitalization with fluctuations between 226 and 1,722 IU (normal of 60 to 250 IU). Urine amylase levels were proportionately elevated and the amylase clearance was normal [1]. A sternal marrow aspirate was obtained without difficulty. Both clot sections and smears demonstrated a moderately hypercellular bone marrow with moderate myeloid hyperplasia and scattered ill-defined focal areas of small immature round cells with scanty cytoplasm, round or somewhat cleft nuclei and often 1 or 2 nucleoli, approximating the appearance of hematopoietic stem cells as described by Dicke et al. [2]. On a differential count of the smears, these cells accounted for 22 per cent of all cells with another 11 per cent identified as bone marrow "lymphocytes." A silver stain was negative for reticulin. The complete blood count and peripheral blood cell morphology were normal with a leukocyte alkaline phosphatase score of 165 IU (normal 13 to 130 IU). Five days later an easily obtained bone marrow aspirate and Jamshidi trephine biopsy specimen from the right posterior iliac crest demonstrated a markedly hypercellular marrow with virtually no fat, generalized hyperplasia of erythroid, myeloid and megakaryocytic cell lines without evidence of maturation arrest or the immature elements observed in the sternal specimen. The silver stain of the biopsy specimen revealed some focal areas of 1+ to 2+ reticulin staining immediately adjacent to bony trabeculae but otherwise was negative. Unfortunately, the marrow culture preparation produced no usable mitoses for karyotypic analysis. Except for moderate anemia, the complete blood count and peripheral morphology remained within normal limits.

On the eighth hospital day, the serum calcium level began to rise (Figure 1) despite the continuous vigorous saline diuresis. The patient again became lethargic and experienced generalized muscular pain. A bone scan with technetium 99m pertechnetate disclosed no abnormalities except for two focal areas of increased uptake in the rib cage which subsequently proved to be old healed rib fractures. In the face of no definitive cause for the hypercalcemia, the patient underwent surgical exploration of the neck on the 11th day and four parathyroid glands, normal in size and histology, were identified in the specimen submitted for tissue examination. Despite the total parathyroidectomy and continuing massive

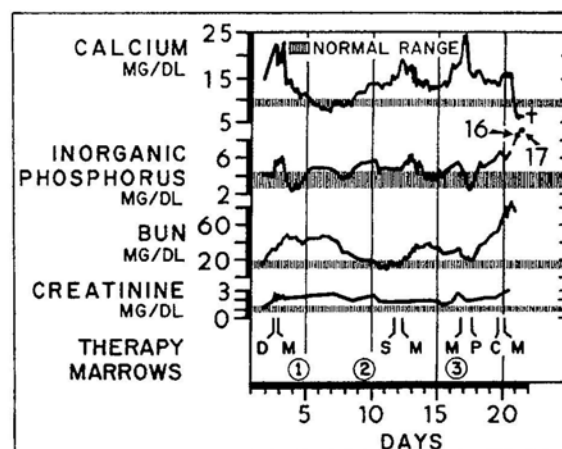


Figure 1. Clinical course indicating serum calcium, inorganic phosphorus, blood urea nitrogen and creatinine in relation to major clinical, diagnostic and therapeutic events during the 21 day hospitalization. D = initiation of diuresis with saline infusion and furosemide. M = individual courses of intravenous mithramycin 50 μ g/kg. S = surgical exploration of the neck and total parathyroidectomy. P = initiation of oral prednisone and allopurinol therapy. C = single course of intravenous cytosine arabinoside 3 mg/kg and oral thioguanine 2.5 mg/kg. ① = initial sternal marrow aspiration. ② = iliac crest marrow aspiration and biopsy. ③ = repeat sternal marrow aspiration and biopsy.

diuresis, the calcium level continued to rise postoperatively, necessitating repeated mithramycin therapy. On the 14th day a biopsy specimen of a bleeding rectal ulceration was obtained which showed extensive underlying soft tissue calcium deposits. Coagulation studies, including platelet function studies, disclosed no abnormalities. On the 16th day a repeat bone marrow aspiration was attempted from several different segments of the sternum, but only a few drops of sinusoidal blood could be aspirated from any one site. The differential count of this scanty specimen was identical to that in the first sternal aspirate. A tiny specimen obtained by sternal trephine suggested myelofibrosis and demonstrated increased reticulin formation. Except for a few myelocytes and metamyelocytes, and rare nucleated red cells, morphologically the peripheral blood remained normal with no evidence of tear drop forms. Serum levels of muramidase, folate and vitamin B₁₂ were within normal limits.

Four units of packed red blood cells were given at the time of the parathyroidectomy and in the immediate postoperative period, but the hemoglobin level continued to fall at a rate greater than expected from the degree of iatrogenic blood loss, suggesting some combination of decreased red cell production and accelerated destruction, however, insufficient to depress the haptoglobin or increase the serum bilirubin. The Coombs' antiglobulin test result was negative, and the maximum recorded reticulocyte count was 1.6 per cent. The patient subsequently received 4 more units of packed red cells during his illness.

PTH levels, as determined by radioimmunoassay by the Mayo Medical Laboratories from blood samples drawn before




Figure 2. Postmortem aspirate from rib with replacement of normal marrow elements by small mononuclear blasts and a prominent increase in osteoclasts. Wright's stain; original magnification $\times 400$, reduced by 53 per cent.

and five days after total parathyroidectomy, were inappropriately high with values of 25 and 28 μl eq/ml, respectively, when serum calcium levels were 14 to 15 mg/dl. Ordinarily, no PTH should be detectable under these conditions [3].

When the diagnosis of an unusual and rapidly progressive acute myeloproliferative disorder became apparent, the administration of prednisone, 160 mg, and allopurinol, 300 mg, daily was begun on the 17th hospital day without any effect on the calcium level; on the 19th day a single dose of cytosine arabinoside, 3 mg/kg intravenously, and thioguanine, 2.5 mg/kg orally, was given. Early on the 20th day another dose of mithramycin was given intravenously. Later that morning the patient became extremely tachypneic with evidence of pulmonary edema followed by cardiac arrest and complete atrioventricular dissociation. He was successfully resuscitated but subsequently remained anuric; severe hy-

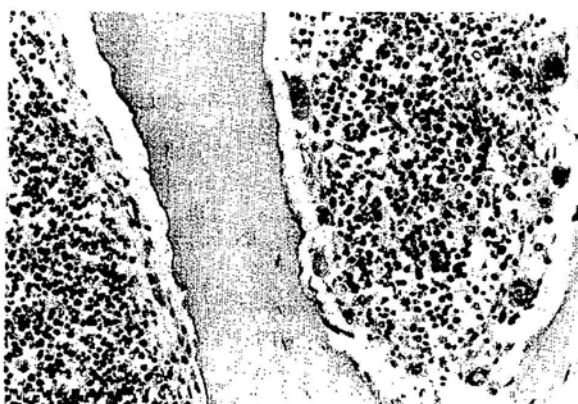


Figure 3. Postmortem section of vertebral body with markedly hypercellular bone marrow with increased erythroid and myeloid elements, large numbers of osteoclasts with extensive erosions (Howship's lacunas) of the bony trabeculas. Hematoxylin and eosin stain; original magnification $\times 160$, reduced by 53 per cent.

perphosphatemia of 17 mg/dl and hypocalcemia of 6.7 mg/dl developed, and he died early on the 21st hospital day, just one month after the initial onset of symptoms. A peripheral blood sample obtained shortly before his death was assayed for osteoclast activating factor (OAF) by Dr. Lawrence G. Raisz, utilizing the fetal rat in vitro tissue culture system [4], and was found negative. In addition, prostaglandin E_2 was not detectable in the peripheral plasma.

Gross postmortem examination revealed marked pulmonary edema and bilateral pleural effusions but was otherwise unremarkable. A thorough search failed to reveal any additional parathyroid tissue. The spleen was slightly enlarged with passive congestion, and the lymph nodes and liver appeared normal. The skeleton was grossly normal except for two old healed rib fractures with considerable callous formation. Postmortem bone marrow aspiration was attempted from at least a dozen areas and produced dry taps except from two sites. On Wright's-stained smears, one of these demonstrated hypercellular normal appearing bone marrow elements with large numbers of osteoclasts. Occasional frankly megaloblastic erythroid precursors were seen and were thought to be related to the cytosine arabinoside therapy. The other site revealed numerous osteoclasts scattered among a monotonous field of small undifferentiated blastic cells with scanty cytoplasm similar to those seen previously during life in the sternum (Figure 2). On section the bone marrow was markedly hypercellular. In some areas increases in all hematopoietic cell lines were seen with a modest or no shift to the left, whereas other areas were replaced by small mononuclear blast cells. The bony trabeculas demonstrated extensive erosion and scalloping (Howship's lacunas) with large numbers of adjacent osteoclasts (Figure 3). Moderate to marked reticulin formation was demonstrated throughout the entire bone marrow although collagen fibers were not seen. Microscopically the lungs revealed marked pulmonary edema with focal areas of bronchopneumonia. Extensive deposition of calcium was demonstrated in the myocardium, stomach, intestines, kidneys, bladder, prostate and skeletal muscle with a marked predilection for muscle, whether smooth, cardiac or striated. The pancreas was normal. Except for some small foci of myeloid precursors with a few normoblasts without megakaryocytes in the red pulp of the spleen, there was no evidence of extramedullary hematopoiesis or neoplastic infiltration outside the bone marrow.

COMMENTS

Although hypercalcemia is a common complication of certain malignancies [5-7], with the exception of multiple myeloma, the association with myelo- or lymphoproliferative disorders is infrequent [8,9]. Osteolytic lesions secondary to hematopoietic or lymphoid neoplasia are quite uncommon other than in multiple myeloma and in some cases of acute lymphoblastic leukemia in children, Hodgkin's disease, large cell ("histiocytic") and Burkitt's lymphomas, despite the fact that the marrow frequently is extensively infiltrated by neoplastic tissue [10,11]. Thus, osteolytic activity and hypercalcemia are not simply related to intramedullary

TABLE I Reported Cases of Hypercalcemia Associated with Myeloproliferative Disorders

Case No.	Reference	Date	Age (yr) and Sex	Peak Calcium (mg/dl)	Disorders
1	Doub, Hartman [38]	1935	51,F	13.7	"Aleukemic myelosis" (myelofibrosis?)
2	Doub, Hartman [38]	1935	17,M	11.5	Acute granulocytic leukemia
3	Kronfield, Reynolds [41]	1964	14,M	18.7	Acute granulocytic leukemia
4	Jordan [42]	1966	33,M	13.1	Acute granulocytic (or undifferentiated) leukemia
5	Jordan [42]	1966	47,M	11.9	Acute granulocytic leukemia
6	Ballard, Marcus [43]	1970	31,M	14.9	Chronic granulocytic leukemia
7	Ballard, Marcus [43]	1970	40,M	21.5	Chronic granulocytic leukemia
8	Steinberg et al. [44]	1971	40,M	15.0	Chronic granulocytic leukemia in acute blastic phase
9	Haskell et al. [45]	1971	44,F	12.1	Chronic granulocytic leukemia in acute blastic phase
10	Haskell et al. [45]	1971	52,M	13.8	Chronic granulocytic leukemia in acute blastic phase
11	Neiman, Li [12]	1972	13,M	17.0	Acute undifferentiated leukemia
12	Palva, Salokannel [46]	1972	15,M	15.6	Acute granulocytic leukemia
13	Allen et al. [47]	1973	80,F	14.2	Acute myelomonocytic leukemia
14	Kawashima et al. [48]	1973	24,F	18.0	Acute granulocytic leukemia
15	Licht et al. [39]	1973	40,F	14.2	Chronic granulocytic leukemia with terminal myelofibrosis
16	Souillet et al. [49]	1973	14,F	16.5	Acute granulocytic leukemia
17	Greul, Lozano-Tonkin [50]	1974	63,M	16.6	Acute aleukemic monocytic leukemia
18	McKee [51]	1974	49,M	14.6	Acute granulocytic leukemia
19	McKee [51]	1974	58,M	15.6	Chronic granulocytic leukemia in acute blastic phase
20	Present case		33,M	22.5	Acute myelofibrosis

cell numbers and mechanical erosion of bone, but rather to cell type and presumably one or more cell products which lead to these sequelae. Factors suggested as causes of osteolysis and hypercalcemia in malignancy are PTH or PTH-like substances [3,12], prostaglandin E₂ [13], a specific osteoclastic activating factor [14,15], some other non-PTH hormone [16], or an imbalance of the various normal factors operating on skeletal and mineral homeostasis [17,18]. The inappropriately high serum PTH level before and after total parathyroidectomy in our case suggests that PTH or a PTH-like substance was produced by the abnormal hematopoietic cells. The negative assay of the peripheral blood for osteoclastic activating factor activity does not rule out the strictly intramedullary production of such a factor or its inactivation or destruction in the peripheral blood. The *in vitro* demonstration by Mundy et al. [15] of an osteoclastic activating factor from myelomatous tissue was not accompanied by any such substance detectable in the peripheral blood of the same patients. However, to date, all cells reportedly producing osteoclastic activating factor have been lymphoid in origin [19,20]. Whether some inducer of prostaglandin E₂ synthesis also was present cannot be absolutely ruled out since no trial with indomethacin, a potent inhibitor of prostaglandin E synthesis, was attempted in this patient. However, the prostaglandin E₂ level in the peripheral blood was not elevated.

Acute myelofibrosis is a rare and somewhat controversial myeloproliferative disorder only recently delineated as an entity by Lewis and Szur [21] and others [22-31], although similar cases can be found in the older literature [32-35]. Some of these patients demonstrated an accelerated development of myelofibrosis otherwise morphologically or clinically indistinguishable from the classic more insidious variety. The other more distinctive group displayed coexistent features of myelofibrosis and a prominent blastic component, at least in focal areas, distinct from the 6 to 20 per cent of the patients in whom an acute blastic terminal phase develops only years after the onset of classic myelofibrosis with myeloid metaplasia [36] or from those patients with acute leukemia and increased marrow reticulin fiber formation [37]. Our patient's bone marrow picture of a striking panmyelosis with the generalized reticulin fiber formation, focal accumulations of blastic cells and elevated leukocyte alkaline phosphatase level is consistent with the diagnosis of acute myelofibrosis. As noted by others [27], the rapidity of the course and early death of the patient probably accounts for the lack of significant extramedullary hematopoiesis or the development of collagen fibers. In the absence of symptomatic hypercalcemia, clinical and laboratory abnormalities revealing the nature of the underlying myeloproliferative disorder might not have become apparent for some time.

Hypercalcemia has not been reported as a complication of myelofibrosis except possibly for a case described by Doub and Hartman [38] in 1935 as "aleukemic myelosis," one of the older designations for myelofibrosis with myeloid metaplasia, although apparently no special stains for reticulin fibers or collagen were made. The other possible exception is a patient with chronic granulocytic leukemia and terminal myelofibrosis [39]. Unfortunately, an autopsy was denied in that patient, and a terminal nonleukemic blastic transformation as found in most of the patients evaluated by Gralnick et al. [40] could not be ruled out. The incidence of hypercalcemia with all myeloproliferative disorders is extremely low. A review of the world literature uncovered only 19 cases reported to date in addition to the present case (Table I). The mechanism leading to hypercalcemia is not indicated in any of the 19 except for the case of acute leukemia described by Neiman and Li [12] in which excessive PTH or PTH-like activity was demonstrated. In at least 17 of the 20 cases the presence of a sizable population of blastic cells was documented when the hypercalcemia developed. This suggests that the potential to produce substances leading to osteolysis tends to be a property of the earlier cellular stages of hematopoiesis. This is supported by the extreme rarity of frankly osteolytic lesions proved microscopically to be due to chronic myeloproliferative disorders lacking a significant blastic component [52-54].

In about half of the cases of classic "agnogenic" myeloid metaplasia, not only myelofibrosis but also osteosclerosis is demonstrated [55-57]. Contrary to the original concept of the myeloproliferative syndromes [58], the fibroblastic response in myelofibrosis appears not to be neoplastic but rather a secondary reactive phenomenon [26], similar to the desmoplastic reaction seen with many other neoplasms [59-63]. The proliferating clone of hematopoietic cells in myelofibrosis and in some cases of chronic granulocytic leukemia [40] and polycythemia vera [64] stimulate local fibroblastic and less often osteoblastic activity by as yet undefined mechanisms. It is unknown whether these responses are mediated through cell-cell interaction, elaboration of toxic substances or short range hor-

mones. Many of the hormonal substances produced by hematopoietic or lymphoid cells, such as osteoclastic activating factor [14,15,19,20] and certain other of the lymphokines [65], and the "chalone" involved in intramedullary control of granulopoiesis [66] exert a strictly local effect due to either inactivation or dilution away from the site of production, making their isolation and identification difficult. According to current hypothesis [17], osteoblasts derive from osteoclasts by a process "modulated" by mechanical stress, calcitonin, inorganic phosphate, growth hormone, estrogen and inhibited by PTH and osteoclastic activating factor. The enhanced proliferation of the progenitor of the osteoclastic-osteoblastic-osteocytic cell line in myelofibrosis and the simultaneous production of a PTH-like substance in our patient may account for the intensity of the osteoclastic and osteolytic response.

The terminal severe hypocalcemia in our patient could be accounted for by the inhibition of PTH-like action on the osteoclasts and osteocytes by mithramycin, halting calcium mobilization [67], the cessation of further PTH production and the possible binding of plasma calcium by phosphates released from the cytoplasm of damaged or killed neoplastic cells. Marked hyperphosphatemia following chemotherapy has been well documented recently in cases of acute leukemia [68,69], lymphocytic lymphoma [70] and Burkitt's lymphoma [71] and was considered to be the responsible mechanism in this case [72]. To what degree the terminal hyperphosphatemia contributed to the extensive deposition of calcium salts in the soft tissue found at autopsy is uncertain, in part because microscopic soft tissue calcification on biopsy was already evident earlier in the course, and in part because of the uncertainty of how hyperphosphatemia produces the fall in serum calcium levels [73].

ACKNOWLEDGMENT

We are gratefully indebted to Dr. Bertram H. Dessel, Dr. Margaret G. Heckman and Dr. Otto F. Gombas for their assistance in obtaining, preparing and interpreting the histologic material, to Dr. Andrew J. Lonigro for the assay for prostaglandin E₂ and to Carole Russell Hilmer for the preparation of the graphic art.

REFERENCES

1. Levitt MD, Rapoport M, Cooperband SR: The renal clearance of amylase in renal insufficiency, acute pancreatitis and macroamylasemia. *Ann Intern Med* 71: 919, 1969.
2. Dicke KA, van Noord MJ, Maat B, et al.: Identification of cells in primate bone marrow resembling the hemopoietic stem cell in the mouse. *Blood* 42: 195, 1973.
3. Benson RC Jr, Riggs BL, Pickard BM, et al.: Radioimmunoassay of parathyroid hormone in hypercalcemic patients with malignant diseases. *Am J Med* 56: 821, 1974.
4. Raisz LG, Niemann I: Effect of phosphate, calcium and magnesium on bone resorption and hormonal responses in tissue culture. *Endocrinology* 85: 446, 1969.
5. Woodard HQ: Changes in blood chemistry associated with carcinoma metastatic to bone. *Cancer* 6: 1219, 1953.
6. Meyers WPL: Hypercalcemia in neoplastic disease. *Arch Surg* 80: 308, 1960.
7. Warwick OH, Yendt ER, Olin JS: The clinical features of hypercalcemia associated with malignant disease. *Can Med Assoc J* 85: 719, 1961.
8. Canellos GP: Hypercalcemia in malignant lymphoma and

- leukemia. *NY Acad Sci* 230: 240, 1974.
9. Walker JR: Lymphoma with hypercalcemia. *Can Med Assoc J* 111: 928, 1974.
10. Moses AM, Spencer H: Hypercalcemia in patients with malignant lymphoma. *Ann Intern Med* 59: 531, 1963.
11. Silverstein MN, Kelly PJ: Leukemia with osteoarticular symptoms and signs. *Ann Intern Med* 59: 637, 1963.
12. Neiman RS, Li HC: Hypercalcemia in undifferentiated leukemia. Possible production of a parathormone-like substance by leukemic cells. *Cancer* 30: 942, 1972.
13. Brereton HD, Halushka PV, Alexander RW, et al.: Indomethacin-responsive hypercalcemia in a patient with renal-cell carcinoma. *N Engl J Med* 291: 83, 1974.
14. Mundy GR, Luben RA, Raisz LG, et al.: Bone-resorbing activity in supernatants from lymphoid cell lines. *N Engl J Med* 290: 867, 1974.
15. Mundy GR, Raisz LG, Cooper RA, et al.: Evidence for the secretion of an osteoclast stimulating factor in myeloma. *N Engl J Med* 291: 1041, 1974.
16. Powell D, Singer FR, Murray TM, et al.: Nonparathyroid humoral hypercalcemia in patients with neoplastic disease. *N Engl J Med* 289: 176, 1973.
17. Rasmussen H, Bordier P: The cellular basis of metabolic bone disease. *N Engl J Med* 289: 25, 1973.
18. Rasmussen H, Bordier P, Kurokawa K, et al.: Hormonal control of skeletal and mineral homeostasis. *Am J Med* 56: 751, 1974.
19. Horton JE, Raisz LG, Simmons HA, et al.: Bone resorbing activity in supernatant fluid from cultured human peripheral blood leukocytes. *Science* 177: 793, 1972.
20. Luben RA, Mundy GR, Trummel CL, et al.: Partial purification of osteoclast-activating factor from phytohemagglutinin-stimulated human leukocytes. *J Clin Invest* 53: 1473, 1974.
21. Lewis SM, Szur L: Malignant myelosclerosis. *Br Med J* 2: 472, 1963.
22. Dameshek W, Gunz F: *Leukemia*, 2nd ed, New York, Grune & Stratton, 1964, p 389.
23. Kahn MH, Martin H: Multiple chromosomal aberrations in a case of malignant myelosclerosis. *Acta Haematol (Basel)* 39: 299, 1968.
24. Aufdermaur M: Osteomyelosclerosis. Chronic and malignant developmental forms. *Fortschr Geb Roentgenstr Nuklearmed* 101: 66, 1964.
25. Mitus WJ, Coleman N, Kiossoglou KA: Abnormal (marker) chromosomes in two patients with acute myelofibrosis. *Arch Intern Med* 123: 192, 1969.
26. Van Slyck EJ, Weiss L, Dully M: Chromosomal evidence for the secondary role of fibroblastic proliferation in acute myelofibrosis. *Blood* 36: 729, 1970.
27. Bergsman KL, Van Slyck EJ: Acute myelofibrosis. An accelerated variant of agnogenic myeloid metaplasia. *Ann Intern Med* 74: 232, 1971.
28. Ascari E, Fontana G, Silingardi V, et al.: Idiopathic myelofibrosis in pediatric age. *Haematologica (Pavia)* 57: 1, 1972.
29. Rothenberger W, Klöppel G: Delimitation of osteomyelosclerosis and sarcomatosis. *Med Klin* 67: 1480, 1972.
30. Gorius JB, Daniel MT, Flandrin G, et al.: Fine structure and peroxidase activity of circulating micromegakaryoblasts and platelets in a case of acute myelofibrosis. *Br J Haematol* 25: 331, 1973.
31. Estevez JM, Ureta EE, Moran TJ: Acute megakaryocytic myelofibrosis. *Am J Clin Pathol* 62: 52, 1974.
32. Churg J, Wachstein M: Osteosclerosis, myelofibrosis and leukemia. *Am J Med Sci* 207: 141, 1944.
33. Wood EE, Andrews CT: Subacute myelosclerosis. Report of three cases. *Lancet* 2: 739, 1949.
34. Rosenberg HS, Taylor FM: The myeloproliferative syndrome in children. *J Pediatr* 52: 407, 1958.
35. Pitcock JA, Reinhard EH, Justus BW, et al.: A clinical and pathological study of seventy cases of myelofibrosis. *Ann Intern Med* 57: 73, 1962.
36. Silverstein MN, Brown AL Jr, Linman JW: Idiopathic myeloid metaplasia. Its evolution into acute leukemia. *Arch Intern Med* 132: 709, 1973.
37. Sanerkin NG: Stromal changes in leukaemic and related bone marrow proliferations. *J Clin Pathol* 17: 541, 1964.
38. Doub HP, Hartman FW: Lymphocytic, myelocytic and monocytic neoplasms. Roentgen diagnosis and treatment. *JAMA* 105: 942, 1935.
39. Licht A, Many N, Rachmilewitz EA: Myelofibrosis, osteolytic bone lesions and hypercalcemia in chronic myeloid leukemia. *Acta Haematol (Basel)* 49: 182, 1973.
40. Gralnick HR, Harbor J, Vogel C: Myelofibrosis in chronic granulocytic leukemia. *Blood* 37: 152, 1971.
41. Kronfield SJ, Reynolds TB: Leukemia and hypercalcemia. Report of a case and review of the literature. *N Engl J Med* 271: 399, 1964.
42. Jordan GW: Serum calcium and phosphorus abnormalities in leukemia. *Am J Med* 41: 381, 1966.
43. Ballard HS, Marcus AJ: Hypercalcemia in chronic myelogenous leukemia. *N Engl J Med* 282: 663, 1970.
44. Steinberg D, Ososky M, Rubin AD: Acute phase of chronic granulocytic leukemia. Onset signaled by hypercalcemia and multiple osteolytic lesions. *NY State J Med* 71: 583, 1971.
45. Haskell CM, DeVita VT, Canellos GP: Hypercalcemia in chronic granulocytic leukemia. *Cancer* 27: 872, 1971.
46. Palva IP, Salokannel SJ: Hypercalcemia in acute leukemia. *Blut* 24: 209, 1972.
47. Allen EL, Metz EN, Balcerzak SP: Acute myelomonocytic leukemia with macroglobulinemia, Bence Jones proteinuria and hypercalcemia. *Cancer* 32: 121, 1973.
48. Kawashima K, Ueda R, Yoshikawa H, et al.: Hypercalcemia in acute leukemia. *Jap J Clin Hematol* 14: 903, 1973.
49. Souillet G, Germain D, Frederich A, et al.: Hypercalcemia and hypocalcemia in acute leukemia in the child. *Lyon Med* 229: 301, 1973.
50. Greul W, Lozano-Tonkin C: Hypercalcaemic crisis as primary manifestation of acute leukaemia in an adult. *Dtsch Med Wochenschr* 99: 287, 1974.
51. McKee LC Jr: Hypercalcemia in leukemia. *South Med J* 67: 1076, 1974.
52. Nesbitt J III, Roth RE: Solitary lytic bone lesion in an adult with chronic myelogenous leukemia. *Radiology* 64: 724, 1955.
53. Campbell E Jr, Maldonado W, Suhland G: Painful lytic bone lesion in an adult with chronic myelogenous leukemia. *Cancer* 35: 1354, 1975.
54. Uthgenannt H, Callsen G: Atypical radiological findings in osteomyelosclerosis. *Fortschr Geb Roentgenstr Nuklearmed* 117: 331, 1972.
55. Rosenthal N, Erf LA: Clinical observations on osteopetrosis and myelofibrosis. *Arch Intern Med* 71: 793, 1943.
56. Jacobson HG, Fateh H, Shapira JH, et al.: Agnogenic myeloid metaplasia. *Radiology* 72: 716, 1959.
57. Pettigrew JD, Ward HP: Correlation of radiologic, histologic and clinical findings in agnogenic myeloid metaplasia. *Radiology* 93: 541, 1969.
58. Dameshek W: Some speculations on the myeloproliferative syndromes. *Blood* 6: 372, 1951.
59. Erf LA, Herbut PA: Primary and secondary myelofibrosis (a clinical and pathological study of thirteen cases of fibrosis of the bone marrow). *Ann Intern Med* 21: 863, 1944.
60. Kiely JM, Silverstein MN: Metastatic carcinoma simulating agnogenic myeloid metaplasia and myelofibrosis. *Cancer* 24: 1041, 1969.
61. Spector JJ, Levine PH: Carcinomatous bone marrow invasion simulating acute myelofibrosis. *Am J Med* 266: 145,

- 1973.
62. Tobin MS, Tan C, Argano SAP: Myelofibrosis in pediatric age group. *NY State J Med* 69: 1080, 1969.
63. Duhamel G: Lymphoid myelofibrosis (about 10 further observations). *Acta Haematol* 45: 89, 1971.
64. Silverstein MN: Post polycythemia myeloid metaplasia. *Arch Intern Med* 134: 113, 1974.
65. Valentine FT: Soluble factors produced by lymphocytes. *Ann NY Acad Sci* 221: 317, 1974.
66. Rytömaa T: Role of chalone in granulopoiesis. *Br J Haematol* 24: 141, 1973.
67. Robins PR, Jowsey J: Effect of mithramycin on normal and abnormal bone turnover. *J Lab Clin Med* 82: 576, 1973.
68. Zusman J, Brown DM, Nesbit ME: Hyperphosphatemia, hyperphosphaturia and hypocalcemia in acute leukemia. *N Engl J Med* 289: 1335, 1973.
69. Armata J, Depowska T: Hyperphosphatemia and hypocalcemia in neoplastic disorders. *N Engl J Med* 298: 858, 1974.
70. Muggia FM, Chia GA, Mickley DW: Hyperphosphatemia and hypocalcemia in neoplastic disorders. *N Engl J Med* 290: 857, 1974.
71. Brereton HD, Anderson T, Jonnson RE, et al.: Hyperphosphatemia and hypocalcemia in Burkitt's lymphoma. Complications of chemotherapy. *Arch Intern Med* 135: 307, 1975.
72. Ajlouni K, Millman WL, Libnoch JA, et al.: Hyperphosphatemia and hypocalcemia in myeloproliferative disorder. *Ann Intern Med* 81: 119, 1974.
73. Hebert LA, Lemann J Jr, Petersen JR, et al.: Studies of the mechanism by which phosphate infusion lowers serum calcium concentration. *J Clin Invest* 45: 1886, 1966.