A case of ovarian enlargement in severe primary hypothyroidism and review of the literature

To the Editor: The association of massive cystic ovarian enlargement with primary hypothyroidism is infrequently reported and not widely recognized in the adult medical or gynecologic literature. At present the exact mechanism leading to ovarian cyst formation in patients with primary hypothyroidism remains uncertain. The clinical findings in patients with severe primary hypothyroidism complicated by massively enlarged ovaries and pituitary can lead to surgery for ovarian cysts or occasionally operation aimed at pituitary adenoma. We report a case of ovarian cyst enlargement associated with severe primary hypothyroidism and review the literature.

A 19-year-old female patient with menarche at the age of 12 years and irregular menstrual cycles presented with 4-year long complaints of generalized pain, swelling in the hands and feet, cold intolerance, decreased activity, excessive sleepiness, short stature, loss of hair and dry skin. She underwent an ultrasound examination for the recent complaint of lower abdominal pain, which revealed large ovaries with multiple cysts. She was scheduled for oophorectomy.

On examination her height was 143.5 cm, bone age lagged by 5 years behind chronological age, the body mass index was 23.3 kg/m^2 with fully developed secondary sexual characteristics, and she had puffy eyes with dry scaly skin. Her laboratory tests showed undetectable free thyroxine (normal, 9.1-23.8 pmol/L), thyroid stimulating hormone (TSH) was 4191.5 mIU/L (normal, 0.47-5.01) with positive antimicrosomal antibodies, prolactin was 38.1 µg/L (normal, 3.8-23.2), and 17-β estradiol was 127.5 pmol/L (normal follicular phase, 110-367). The figure shows the luteinizing hormone (LH) and FSH levels during gonadotropin-releasing hormone (GnRH) stimulation test before and after treatment. Pituitary magnetic resonance imaging (MRI) showed homogenous generalized enlargement of the pituitary gland. A pelvic computed tomography (CT) scan showed multiple bilateral ovarian cysts, the right ovary was 4.5 x 4 cm and the left ovary was 5 x 4 cm. The patient was diagnosed as having primary hypothyroidism with ovarian cystic enlargement. Treatment with thyroxine was initiated under close monitoring and the patient showed marked clinical improvement and normal menses. After six months, a repeat MRI showed a normal pituitary gland and a pelvic CT scan showed complete disappearance of the right ovarian cysts with two cysts remaining in the left ovary.

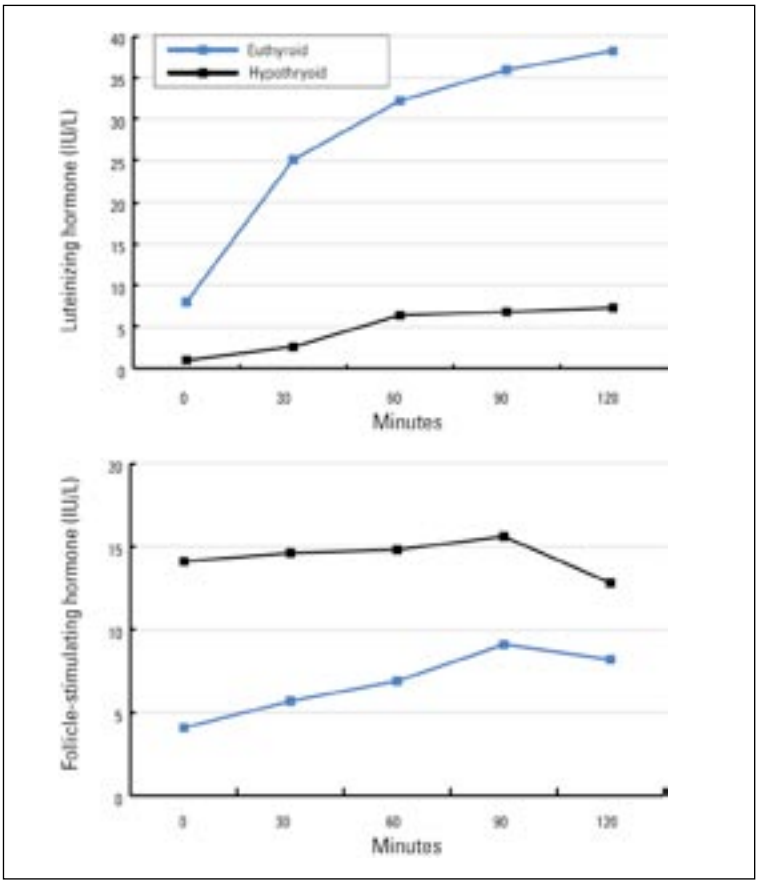

Figure 1. GnRH stimulation test before (hypothyroid) and after thyroxine treatment (euthyroid) (by IV administration of 100 µg with assessment of LH and FSH levels at 0, 30, 60, 90, 120 minutes).

Only 4 cases of massive ovarian enlargement have been reported in nonpregnant women with hypothyroidism (Table 1).[1,2,3,4] These patients were similar to our case, who had severe hypothyroidism of long duration, as evidenced by retarded growth and delayed skel-

etal maturity. They had massively enlarged cystic ovaries, abdominal pain and mild ascites. Pituitary enlargement due to thyrotroph cell hyperplasia in primary hypothyroidism is caused by a decrease in the negative feedback exerted by circulating thyroid hormones. Our case had massive pituitary enlargement that regressed rapidly with thyroxine treatment, while ovarian cysts persisted for several months. We have previously shown that complete resolution of ovarian enlargement may require one year.[4]

Ovarian enlargement in severe primary hypothyroidism is probably due to stimulation of FSH receptors by unusually high levels of TSH, which was proved to have weak FSH-like activity.[5] Other investigators have proposed that patients who have ovarian hyperstimulation syndrome due to hypothyroidism may have a mutation in the FSH receptor that may further increase the sensitivity of the receptor to TSH.[6,7]

Pathological examination of ovarian tissue from a similar case revealed non-luteinized ovarian cysts accompanied by extensive myxedematous infiltration in both ovaries.[3] These pathological features indicate that polycystic ovarian disease may be a misnomer, since the mechanism is probably quite different. Ovarian hyperstimulation could be the result of nonspecific overproduction of all the pituitary hormones by the tumor-like generalized enlargement of the pituitary,[8] which was evident in our patient. However, this mechanism is unlikely since the levels of basal and stimulated gonadotropins in our patients and other patients reported in the literature were within normal limits or suppressed (Table 1). Moreover, with thyroxine treatment and the resolution of ovarian enlargement we noticed an exaggerated response of gonadotropins to GnRH stimulation. Elevated prolactin levels in patients with severe hypothyroidism may be an etiologic factor in ovarian hyperstimulation;[9] however, massive ovarian enlargement is not a recognized feature in prolactinomas with higher levels of prolactin.

Markedly elevated serum levels of estradiol are found in most cases of ovarian hyperstimulation syndrome.[10] Our case and three of the patients described in Table 1 had normal serum estradiol, which has also been found in cases of ovarian enlargement owing to FSH receptor stimulation.[11,12] In conclusion, awareness that ovarian and pituitary enlargement can be caused by severe hypothyroidism will spare patients dangerous and unnecessary operative intervention.

Taher Bassam
Kamel Ajlouni
The National Center for Diabetes
Endocinology and Genetics
Jordan University Hospital
Amman 1339 Tareq
Jordan
drtaher222@yahoo.com

References

1. Rotmensch S, Scommegna A. Spontaneous ovarian hyperstimulation syndrome associated with hypothyroidism. Am J Obstet Gynecol 1989;160(5 Part 1):1220-2.
2. Van Voorhis BJ, Neff TW, Syrop CH, Chapler FK. Primary hypothyroidism associated with multicystic ovaries and ovarian torsion in an adult. Obstet Gynecol 1994;83(5 Part 2):885-7.
3. Hansen KA, Tho SP, Hanly M, Moretuzzo RW, McDonough PG. Massive ovarian enlargement in primary hypothyroidism. Fertil Steril 1997;67(1):169-71.
4. Taher BM, Ghariabeh RA, Jarrah NS, Hadidy AM, Radaideh AM, Ajlouni KM. Spontaneous ovarian hyperstimulation syndrome caused by hypothyroidism in an adult. Eur J Obstet Gynecol Reprod Biol 2004;112(1):107-9.
5. Anasti JN, Flack MR, Froehlich J, Nelson LM, Nisula BC. A potential novel mechanism for precocious puberty in juvenile hypothyroidism. J Clin Endocrinol Metab 1995;80(1):276-9.
6. Vasseur C, Rodien P, Beau I, Desroches A, Gerard C, de Poncheville L, Chaplot S, et al. A chorionic gonadotropin-sensitive mutation in the follicle-stimulating hormone receptor as a cause of familial gestational spontaneous ovar-

Table 1. Clinical and hormonal profile of patients with ovarian hyperstimulation and severe primary hypothyroidism reported in literature (nonpregnant cases only), and our case.

Reference	Age	FSH (IU/L)	LH (IU/L)	Prolactin (µg/L)	Estradiol (pg/mL)	Clinical	Ovary
1	21	19.2	6.2	119	1303	Abdominal pain	Multilobulated, ovarian cysts, rt 10 cm, lt 13.8 cm
2	26	15.7	0.7	36	80	Acute abdomen	Multicystic, rt 14 x 14 cm, lt 11 x 10 cm
3	16	33.6		133.5	104	Pelvic pain	Multicystic enlargement, rt 13 x 10 cm, lt 10 x 9 cm
4	22	9.8	12.6	71.3	150.9	Pelvic pain	Multiloculated ovarian masses, rt 6x4 cm, lt 12 x 9 cm
Our case	19	14.1	1.1	38.1	127	Abdominal pain	Bilateral ovarian cysts, rt 4.5 x 4 cm, lt 5 x 4 cm

ian hyperstimulation syndrome. N Engl J Med. 2003;349(8):753-9.
7. Smits G, Olatunbosun O, Delbaere A, Pierson R, Vassart G, Costagliola S. Ovarian hyperstimulation syndrome due to a mutation in the follicle-stimulating hormone receptor. N Engl J Med. 2003;349(8):760-6.
8. Grumbach MM, Styne DM. Puberty: ontogeny, neuroendocrinology, physiology, and disorders. In: Wilson JD, Foster DW, Kronenberg HM. et al., editors. Williams Textbook of Endocrinology. Philadelphia: Saunders;1998. pp. 1593-594.
9. Barnes ND, Hayles AB, Ryan RJ. Sexual maturation in juvenile hypothyroidism. Mayo Clin Proc. 1973;48(12):849-56.
10. Aboulghar M. Prediction of ovarian hyperstimulation syndrome (OHSS). Estradiol level has an important role in the prediction of OHSS. Hum Reprod 2003;18(6):1140-1.
11. Shoham Z, Balen A, Patel A, Jacobs HS. Results of ovulation induction using human menopausal gonadotropin or purified follicle-stimulating hormone in hypogonadotropic hypogonadism patients. Fertil Steril 1991;56(6):1048-53.
12. Shimon I, Rubinek T, Bar-Hava I, Nass D, Hadani M, Amsterdam A, Harel G. Ovarian hyperstimulation without elevated serum estradiol associated with pure follicle-stimulating hormone-secreting pituitary adenoma. J Clin Endocrinol Metab 2001;86(8):3635-40.

Prevalence of GBV-C/hepatitis G virus viremia among chronic hepatitis B, chronic hepatitis C and hemodialysis patients in Turkey

To the Editor: The newly discovered hepatitis G virus (HGV) or GBV-C are isolates of the same virus, which is a single-stranded RNA virus of positive polarity with 9362 nucleotides.[1] It can be transmitted via blood transfusion and intravenous drug use, sexually, and from an infected mother to her child.[2] High prevalences of GBV-C/HGV have been found in subjects with frequent parenteral exposure and in groups at high risk of exposure to blood and blood products, including drug abusers, hemodialysis patients, multitransfused individuals and haemophiliacs.[3] Due to shared risk factors, coinfection of GBV-C/HGV with hepatitis B (HBV) or hepatitis C (HCV) viruses in chronically infected patients has been reported at frequencies ranging from 10 to 25%.[4]

Because the prevalence of GBV-C/HGV is unclear in Turkish population, we sought analyze the prevalence of GBV-C/HGV-RNA in the sera of different groups in the Turkish population. Three hundred and ten Turkish serum samples classified into four groups were studied. Sera of 85 hemodialysis patients, 80 chronic hepatitis B patients, 75 chronic hepatitis C patients, and 70 healthy persons (control group) were tested for the presence of GBV-C/HGV-RNA. The control group included apparently healthy individuals who had participated in occupational screening for a randomly selected viral hepatitis marker. Thirty-seven were male and 33 female with a mean age of 42.5±11.8 years (range, 20-65 years). None were positive for anti-HCV or for HBsAg.

RNA was extracted from 150 µl of serum using the Nucleospin Virus Kit (Biogene, Kimbolton, UK). Real-time PCR was performed using primer pairs and a probe located in the 5´ untranslated region (5´UTR) of GBV-C/HGV-RNA using the ABI Prism 7700 Sequence Detector System (Perkin Elmer, Foster City, Calif.). Data were analysed by Fisher' s exact test. A *P* value less than 0.05 was considered significant.

GBV-C/HGV-RNA was detected in 52 of the 310 sera tested with an overall prevalence of 17%. The highest prevalence was encountered among chronic hepatitis B patients (28%) followed by hemodialysis patients (24%), chronic hepatitis C patients (6%), whereas the lowest prevalence rate of 4% was detected among healthy persons (Table 1). HGV was significantly more frequent in chronic hepatitis B patients, hemodialysis patients, and chronic hepatitis C patients than in healthy persons ($P<0.05$).

It has been documented that patients with chronic hepatitis often harbor more than one hepatitis agent.[5] The apparent link between hepatotropic viral infections probably reflects common exposure and transmission patterns rather than a specific interdependence relation. Heringlake et al.[6] reported a striking high prevalence of HGV-RNA among patients with viral hepatitis B, C and D reaching 16%, 20% and 36%, respectively. In our study, the prevalence rate of GBV-C/HGV was 7% in the chronic hepatitis C group. The relative low prevalence of GBV-C/HGV-RNA in this group may be explained by a similar reciprocal replication pattern among patients coinfected with HBV and HCV.[7] This had been proposed by Raimondo et al.,[8] who suggested that while long-lasting persistance of HCV is the rule in chronically infected individuals, clearence of GBV-C/HGV after years of chronic infection is a frequent event.

Table 1. GBV-C/HGV RNA positivity among the four groups.

Group	No. tested	HGV RNA	
		No. positive	%
Chronic hepatitis B patients	80	23	29
Chronic hepatitis C patients	75	5	7
Hemodialysis patients	85	21	25
Healthy controls*	70	3	4
Total	**310**	**52**	**17**

P<0.05 versus other groups.

Several authors demonstrated a high prevalence of HGV in hemodialysis patients with a wide range between different countries.[9] Our figure of 25% is similar to that observed in most countries, including Italy[10] and Spain.[11] However, lower and higher prevalences have been reported in other countries: 3% to 8% in Japan and Germany[12,13] and 55% to 57% in Indonesia and France.[14,15] These differences in the prevalence of GBV-C/HGV may be explained by epidemiological variations, including a variable rate of blood transfusions and a variable adherence to universal precautions. However, a methodological reason may also contribute to this variability. In the reported studies, most determinations are performed using noncommercial tests and different primers were amplified. An available commercial kit or at least unified criterion for the detection should be necessary to obtain useful data to compare the prevalence of GBV-C/HGV.

In conclusion, GBV-C/HGV-RNA is highly prevalent among the different Turkish patient populations, being highest in chronic hepatitis B patients. Although much information has been learned about GBV-C/HGV infection in the short time since the discovery of the virus, the clinical and pathological significance of this infection needs better evaluation, particularly in patients infected with other hepatitis viruses, and in hemodialysis patients.

Sinem Akcali
Tamer Sanlidag
Beril Ozbakkaloglu

Correspondence:
Sinem Akcali, MD
Celal Bayar University
Microbiology and Clinical
Microbiology
Koruturk mah. Lodos sok. No:9
D:3
Balcova Izmir 35330 Turkey
akcalisinem@yahoo.com

References

1. Kar P, Bedi P, Berry N, et al. Hepatitis G virus (HGV) infection in voluntary and commercial blood donors in India. Diagn Microbiol Infect Dis. 2000; 38: 7-10.
2. Fabrizi F, Lunghi G, Bacchini G, et al. Hepatitis G virus infection in chronic dialysis patients and kidney transplant recipients. Nephrol Dial Transplant. 1997; 12: 1645-51.
3. Sathar MA, Soni PN, Pegoraro R et al. A new variant of GB virus C/hepatitis G virus (GBV-C/HGV) from South Africa. Virus Research. 1999; 64: 151-60.
4. Bassit L, Bernhard K, Ribeiro-dos-Santos G et al. Hepatitis G virus: Prevalence and sequence analysis in blood donors of Sao Paulo, Brazil. Vox Sang. 1997; 74: 83-7.
5. Linnen J, Wages J Jr, Zhang-Keck ZY et al. Molecular cloning and disease association of hepatitis G virus: a transfusion-transmissible agent. Science.1996; 26: 505-8.
6. Heringlake S, Tillmann HL, Cordes-Temme P et al. GBV-C/HGV is not the major cause of autoimmune hepatitis. J Hepatol. 1996; 25: 980-4.
7. El-Zayadi AR, Abe K, Selim O et al. Prevalence of GBV-C/hepatitis G virus viraemia among blood donors, health care personel, chronic non-B non-C hepatitis, chronic hepatitis C and hemodialysis patients in Egypt. J Virol Methods. 1999; 80: 53-8.
8. Raimondo G, Pernice M, Longo G. Hepatitis G virus in liver disease: Cause or case? Ital J Gastroenterol. 1996; 28: 470-3.
9. Beccari M, Sorgato G. The new HGV/HGVB-C virus in dialysis patients. J Nephrol. 1998; 11: 165-8.
10. Sampietro M, Badalamenti S, Graziani G et al. Hepatitis G virus infection in hemodialysis patients. Kidney Int. 1997; 51: 348-52.
11. Forns X, Fernandez-Llama P, Costa J et al. Hepatitis G virus infection in a hemodialysis unit: prevelance and clinical implications. Nephrol Dial Transplant. 1997; 12: 956-60.
12. Masuko K, Mitsui T, Iwano K et al. Infection with hepatitis GB virus C in patients on maintenance hemodialysis. N Engl J Med. 1996; 334: 1485-90.
13. Ideura T, Tanaka E, Nakatsuji Y et al. Clinical significance of hepatitis G virus infection in patients on long-term hemodialysis. J Gastroenterol Hepatol. 1997; 12: 762-5.
14. Tsuda F, Hadiwandowo S, Sawada N et al. Infection with GB virus C (GBV-C) in patients with chronic liver disease or on maintenance hemodialysis in Indonesia. J Med Virol. 1996; 49: 248-52.
15. de Lamballerie X, Charrel RN, Dussol B. Hepatitis GB virus C in patients on hemodialysis. N Engl J Med. 1996; 334: 1549.

Surfactant protein B deficiency: a rare cause of respiratory failure in a Lebanese newborn

To the Editor: Respiratory diseases secondary to congenital surfactant proteins deficiency are increasingly recognized. To bring to the attention of pediatricians an unusual cause of neonatal respiratory disease, we report on a newborn with progressive respiratory disease due to surfactant protein B (SP-B) deficiency. To our knowledge, this is the first case of SP-B deficiency reported in the Middle East.

The patient was a term female newborn delivered vaginally after an uneventful pregnancy to second-degree consanguineous parents. The mother had a stillbirth and a newborn that died on the second day of life of respiratory causes. Four other siblings are normal. Apgar scores were 5 and 8 at 1 and 5 minutes, respectively. The baby was hypotonic and required vigorous stimulation. Birth weight was 3250 grams. Physical examination was remarkable for tachypnea, cyanosis and bilateral decreased air entry. Chest X-ray showed bilateral fine granular infiltrates.

The baby was started on antibiotics after a sepsis work up. She required conventional and then high frequency oscillatory ventilation because of hypoxemia and CO_2 retention. Echocardiography showed mild right ventricular hypertrophy. On the fourth day of life, she received bovine surfactant (Survanta, Abbott Laboratories, Columbus, Ohio, USA) intratracheally with clinical and radiological improvement that was not sustained on four additional doses. She then received furosemide, hydrocortisone and inhaled nitric oxide with no response. On the seventeenth day of life, she died of persistent hypoxemia with severe respiratory acidosis. Tracheal effluent collected before surfactant administration revealed complete absence of SP-B (Courtesy of

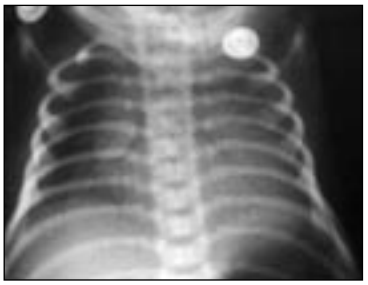

Figure 1. Chest x-ray showing bilateral fine granular infiltrates.

Dr. Jeffrey Whitsett, Cincinnati Children's Hospital). DNA analysis revealed the homozygous 122delT mutation, while both parents were heterozygous for the same mutation (Courtesy of Dr. Lawrence Nogee, Johns Hopkins University).

SP-B is a hydrophobic protein involved in the adsorption of surfactant phospholipids to the air-liquid interface. It is coded by a gene of 11 exons on chromosome 2. In 1993, Nogee et al reported SP-B deficiency causing severe respiratory disease, as described in our patient.[1] The patient and a sibling who had died earlier had a frame-shift mutation caused by a 2 base-pair insertion (121ins2) in exon 4 of the SP-B gene.[2] Radiologically, SP-B deficiency presents like hyaline membrane disease. Histopathologically, the distal airspaces appear filled with lipid-rich, periodic acid Schiff-positive, eosinophilic proteinaceous material.[1]

The diagnosis is established by failing to identify SP-B in the tracheal effluent and is confirmed by genetic studies, which show a mutation on the SP-B gene. More than 13 mutations have been described,[3] of which (121ins2) accounts for about 70%. Its frequency in the United States is estimated to be 1 per 1000-3000 individuals.[4] The 1043ins3 mutation was detected in 2 unrelated Pakistani families.[3] The mutation described in the present report (122delT) was described in a consanguineous kindred of Kurdish descent,[5] and in three unrelated Lebanese families (L. Nogee, personal communication). The recognition of specific mutations in various ethnic groups may allow diagnosis in individual patients and population-wide studies for the determination of gene frequency. This would gain particular importance in our population, where consanguinity is prevalent. SP-B deficiency is usually fatal, unless treated with lung transplantation.[6] Gene transfer therapy may be the treatment modality of the future.

George Ferzli
Khalid A. Yunis
Salman Mroueh

Correspondence:
Salman Mroueh, MD
American University of Beirut
Department of Pediatrics
P.O. Box 11-0236/49B Beirut
Riad El Solh 1107 2020
smroueh@aub.edu.lb

References

1. Nogee LM, deMello DE, Dehner LP, Colten HR: Pulmonary Surfactant Protein B deficiency in congenital pulmonary alveolar proteinosis. N Eng J Med 1993; 328: 406-410.
2. Nogee LM, Garnier G, Dietz HC, Singer L, Murphy AM, deMello DE, et al. A mutation in the surfactant protein B gene responsible for fatal neonatal disease in multiple kindreds. J Clin Invest 1994; 93:1860-1863.
3. Nogee LM, Wert SE, Profitt SA, Hull WM, Whitsett JA: Allelic heterogeneity in hereditary Surfactant Protein B deficiency. Am J Respir Crit Care Med 2000; 161: 973-981.
4. Cole SF, Hamvas A, Rubinstein P, King E, Trusgnich M, Nogee LM, et al. Brief report: population-based estimates of surfactant protein B deficiency. Pediatrics 2000; 105:538-541.
5. Wallot M, Wagenvoort C, deMello D, Muller K-M, Floros J, Roll C. Congenital alveolar proteinosis caused by a novel mutation of the surfactant protein B gene and misalignment of lung vessels in consanguineous kindred infants. Eur J Pediatr 1999; 158: 513-518.
6. Hamwas A, Nogee LM, Mallory GB, Spray TL, Huddleston CB, August A, Colten HR: Lung transplantation for treatment of infants with surfactant protein B deficiency. J Pediatr. 1997; 130: 231-239.

Serum immunoglobulin A, G and M in healthy adults in Dhofar, Oman

To the Editor: There is little data available on normal levels of serum immunoglobulin in the healthy adult populations of the Gulf countries and the Arab world. In many instances, the normal ranges for immunoglobulin, which are used by many hospitals within the Arab world, are those that are supplied by the manufacturer of the equipment or the reagents, and these values may not reflect the normal values of the local populations. Therefore, it is essential that each population establish its own normal values that can be used locally.

Although Oman has a climate that is generally hot and dry, similar to other Gulf Countries, Dhofar's (the southern region of Oman) climate is relatively cool and rainy, particularly during the summer monsoon. Individuals from this part of Oman may have their own distinct levels of immunoglobulin as this region has a distinct pattern of infections.[1]

Serum samples were collected from 489 (389 males and 100 females) Omani healthy adults from Dhofar recruited from healthy blood bank donors attending Sultan Qaboos Hospital in Salalah. Individuals with a history of acute or chronic illness, present or past allergy, parasitic infestation, chronic drug use, or present immunization were excluded from the study. After informed consent was secured, blood samples were obtained and allowed to clot at room temperature. Sera were separated and stored at -20°C until assayed for immunoglobulin G, M, and A, using a rate nephelometry system (Beckman Image System).

The majority of the participants, 54% (n=262), were 20-29 years old, followed by 23% (n=114) that were 30-39 years old and 8% (n=40) were 40-49 years old. Only 5 individuals (1%) were above the age of 50 years, while 68 individuals (14%) were 20 years or younger. The mean age for the whole cohort was 28.6 years (males and females were 29.9 years and 23.6 years, respectively).

The mean serum levels of IgM, IgG, and IgA for the whole cohort are shown in Table 1. The immunoglobulin M, G, and A normal ranges are shown as the range between the 5th and 95th percentile. When we compared serum immunoglobulin levels in individuals below the age of 20 years (n=68), we observed a significant difference with regard to serum IgA levels, which occurred at lower levels in those young individuals compared to those above the age of 20 years (n=421), (P<0.01).

Comparing our results with those obtained from the neighboring Saudi population,[2] similar levels of IgM (1.14 g/L for Saudis versus 1.01 g/L for Omanis) and similar levels for IgA were noted. However, a significantly higher level (P<0.05) of IgG (14.63 g/L for the Saudis versus 12.88g/L for Omanis) was detected. This may be due to environmental factors, since the climate in Saudi Arabia is quite different from the climate in Dhofar. Whereas the climate in Saudi Arabia is hot and dry all year, the climate in Dhofar is cold and rainy most of the year. Therefore, different antigen exposure in the two groups may account for the different levels of IgG. However, data from a cross-sectional study are needed to verify that the Dhofar population are different, per the reviewer comment.

Ali A. Al-Jabri
Shyam S Ganguly

Correspondence:
Dr. Ali A. Al-Jabri, PhD
Department of Microbiology and Immunology,
College of Medicine & Health Sciences, Sultan Qaboos University,
P.O. Box 35, Al Khod,
Muscat 123
Sultanate of Oman.
Tel: +968-515186
Fax: +968-513419
aaljabri@squ.edu.om

References

1. Arthur G, Hamad A, Padma K and Abdullah S. Immunoglobulins, immunoglobulin G subclasses and complement in adult Omanis. [Internet] http://www.kfshrc.edu.sa/annals/171/96-190.htm
2. Harfi HA, Godwin JT. Normal serum levels of IgG, IgA, IgM, IgD, and IgE in Saudi Arabia. King Faisal Specialist Hosp Med J. 1985; 5: 99-105.

N-Butyl-2-Cyanoacrylate (*Histoacryl*) Complication: A Case Report

To the Editor: The tissue adhesive N-butyl-2-cyanoacrylate (*Histoacryl*, Trihawk International, Montreal, Canada) is a well-known and effective modality for treatment of gastric varices secondary to portal hypertension of various causes. It has been used safely in many centers for up to 20 years.[1,2] Nonetheless, in a minority of cases, its use has been associated with adverse effects like portal vein thrombosis. We report on the management of a secondary bleeding complication by placement of a transjugular intrahepatic portosystemic shunt (TIPS).

A 41-year-old woman was referred to our hospital with esophageal and gastric varices secondary to liver disease due to bilharziasis. She had multiple episodes of upper gastrointestinal bleeding. Esophagogastroduodenoscopy identified two esophageal and three gastric varices with evidence

Table 1. Serum IgM, IgG and IgA in healthy adult Omanis (ages 18 to 54 years) from Dhofar, Oman.

Variable	IgM			IgG			IgA		
	Both (n=489)	Males (n=389)	Females (n=100)	Both (n=489)	Males (n=389)	Females (n=100)	Both (n=489)	Males (n=389)	Females (n=100)
Mean	1.006	0.886*	1.471*	12.88	12.85	13.00	2.64	2.57*	2.90*
SD	0.511	0.450	0.468	2.76	2.97	1.71	1.12	1.07	1.27
95% CI	0.960, 1.051	0.841, 0.931	1.378, 1.564	12.63, 13.12	12.55, 13.14	12.66, 13.34	2.54, 2.74	2.47, 2.68	2.65, 3.15
5th Percentile	0.374	0.354	0.647	8.52	8.17	10.41	1.23	1.18	1.50
95th Percentile	2.050	1.640	2.469	17.45	18.30	15.60	4.77	4.72	6.51

Serum immunoglobulin levels are in grams per liter
Asterisks (*) indicate significant difference in values between sexes.

Figure 1. Abdominal radiograph showing dense radiopaque material involving the portal venous circulation of both hepatic lobes.

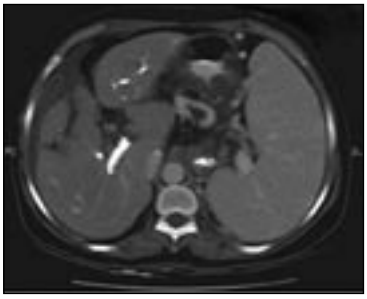

Figure 2. Abdominal CT showing dense material in the right portal vein and a branch of the left portal vein. Splenomegaly and ascites are also present.

of hypertensive gastritis. A total volume of 2.5 cc of cyanoacrylate mixed with Lipiodol in a 1:1 ratio was injected at three different sites in the gastric varices. The patient started complaining of severe central abdominal pain, associated with generalized tenderness and rigidity 30 minutes after the procedure, but was hemodynamically stable. A plain abdominal radiograph obtained immediately showed no evidence of visceral perforation, but there was radio-opaque material widely spread in the distribution of the portal vessels (Figure 1). A CT scan of the abdomen showed multiple areas of dense material in the vessels of the upper abdomen, including the portal vein and its intrahepatic branches, as well as the splenic, splenorenal collaterals, and renal and cardinal veins. Thrombosis of the portal and splenic veins was also seen (Figure 2). Ultrasound Doppler showed hyperechoic material in the portal vein with turbulent blood flow in keeping with thrombosis. The superior mesenteric vein was patent.

The patient responded to analgesia, her symptoms disappeared completely after 7 days, and she was discharged home. The patient was readmitted 5 months later with another episode of upper gastrointestinal bleeding. A repeat CT scan and hepatic ultrasound images showed some resolution of the portal thrombosis. The patient underwent placement of a TIPS. After placement, the patient did well without further bleeding.

Histoacryl injection in the treatment of acute gastric variceal bleeding is safe and cost effective when used according to recommendations, which call for a small volume (<3 mL in total and <1 mL at each site) of *Histoacryl* and Lipiodol in a 1:1 ratio.[3] Nevertheless, the endoscopist must be alert to potential immediate complications like abdominal pain, fever, impaction of the injected needle, distal embolization and acute thrombosis or late complications like venous thrombosis secondary to gastric cyanoacrylate injection.[4,5] Initial hemostasis with this modality of treatment can be achieved in over 90% of patients,[2] obliteration of gastric varices can be achieved in 100%,[7] but rebleeding can occur in about 10%.[6]

In comparison to a TIPS, *Histoacryl* injection therapy has no significant difference in terms of survival rate. It is relatively safe, has comparable rates of severe esophagogastric variceal bleeding[8] and is more cost effective.[9] To our knowledge, this is the first report of a TIPS placement to rescue a patient with major complications following administration of *Histoacryl* injection.

Hamad Al Ashgar
Abdulrahman Kabbani
Yusuf Al Kadhi

Correspondence:
Hamad Al Ashgar, MD
Consultant, Section of Gastroenterology
Department of Medicine
MBC 46
King Faisal Specialist Hospital and Research Centre
PO Box 3354, Riyadh 11211
Kingdom of Saudi Arabia.
Tel: +966-1-4424729
Fax: +966-1-4427499
alashgar@kfshrc.edu.sa

References

1. Ogawa K, Ishikawa S, Naritaka et al. Clinical evaluation of endoscopic injection sclerotherapy using n-butyl-2 cyanoacrylate for gastric bleeding. Journal of gastroenterology and hepatology 1999; 14:245-250
2. Akahoshi T, Hashizume M, Shimabukuro R et al. Long-term results of endoscopic Histoacryl injection sclerotherapy for gastric variceal bleeding: a 10 year experience. Surgery 2002; 131:S176-181
3. Huang Y, Yeh H, Chen G et al. Endoscopic treatment of bleeding gastric varices by N-butyl-2-cyanoacrylate (Histoacryl) injection: long-term efficacy and safety. Gastrointestinal Endoscopy 2000; 52(2): 160-7
4. Shim C, Cho Y, Kim J et al. A case of portal and splenic vein thrombosis after Histoacryl injection therapy in gastric varices. Endoscopy 1996; 28:461
5. Hwang S, Kim H, Park S et al. N-Butyl-2-Cyanoacrylate pulmonary embolism after endoscopic injection sclerotherapy for gastric variceal bleeding. Journal of computer assisted tomography 2001; 25(1): 16-22
6. Dhiman RK, Chawla Y, Taneja S et al. Endoscopic sclerotherapy of gastric vericeal bleeding with N-butyl-2-cyanoacrylate. J Clin Gastroenterol 2002; 35:222-227
7. Sarin SK, Jain AK, Jain M, Gupta R. A Randomized controlled trial of cyanoacrylate versus alcohol injection in patients with isolated fundic varices. Am J Gastroenterol 2002; 97: 1010-1015
8. Noh du Y, Park SY, Joo SY, Park CH et al. Therapeutic effect of the endoscopic N-butyl-2-cyanoacrylate injection for acute esophagogastric variceal bleeding: comparison with transjugular intrahepatic portosystemic shurt. Korean Journal of Gastroenterology/Taehan Sohwagi Hakhoe Chi. 43(3):186-95,2004 Mar.
9. Mahadeva S, Bellamy MC, Kessel D, et al. Cost-effective of N-butyl-2-cyanoacrylate (histoacryl) glue injections versus transjugular intrahepatic portosystemic shunt in the management of acute gastric variceal bleeding. American Journal of Gastroenterology. 98(12):2688-93,2003 Dec.

Anterior chamber depth and intraocular pressure following panretinal argon laser photocoagulation for diabetic retinopathy

To the Editor: Ocular photocoagulation uses heat produced through the absorption of light by ocular pigments. Absorption of light can take place either in the tissue to be photocoagulated or in a neighboring tissue, from which heat is then transferred to the tissue of interest by thermal conduction. Thermal damage is caused by chemical changes that result when the ocular tissues are heated to temperatures high enough to denature proteins or other large molecules.[1-3] A temperature increase of 10ºC to 20ºC is sufficient to produce the desired chemical changes. Photocoagulation is used in the management of retinal diseases such as diabetic retinopathy, diabetic maculopathy, subretinal neovascularization, retinal vascular abnormalities, and retinal breaks or tears of various types.[3] Panretinal argon photocoagulation (PRP) is commonly performed for the treatment of proliferative diabetic retinopathy, ischemic central retinal vein occlusion, and other causes of retinal ischemia.[4] Complications of PRP include thermal injury to the cornea, iris and lens, visual field loss, haemorrhage, macular edema, and elevated intraocular pressure with or without angle closure.[4-6] Many transient changes after PRP occur only when a large area of the retina is treated in one session or in closely spaced sessions.[5] In the study, we investigated the effects of PRP on anterior chamber depth changes and early and late period intraocular pressure.

We studied 170 eyes with diabetic retinopathy (Type 2 diabetes). All patients had proliferative or high-risk preproliferative retinopathy. PRP was applied to all eyes under topical anesthesia. Patients with closed angle, rubeosis iridis, open angle or neovascular glaucoma, and other intraocular disorders were excluded. Examination before and after PRP comprised the fundus, chambers angle, visual acuity, slit-lamp examination, fundus Fluorescein angiography and IOP. IOP was measured with a Goldman applanation tonometer. Eyes with IOP over 30 mm Hg were treated with timolol maleate 0.05%. Anterior chamber depth was evaluated by the same person using A-scan ultrasonography. IOP measurements and anterior chamber depth were measured after cycloplegia. Cycloplegia was applied using cyclopentolate hydrochloride 1%. The intraocular pressure of each eye was measured during the first examination before PRP and at the first hour, first day, and the first, third and sixth months after PRP. Anterior chamber depth was also measured before PRP, and after the first hour and first day after PRP. Patients with an IOP >30 mm Hg were treated by antiglaucomatous agents. The initial treatment protocol of PRP was 850 to 1200 burns, the intensity varied from 0.2 to 1.0 W, the duration of exposure varied from 0.1 to 0.2 second, and the spot size 200 to 500 µ. Additional photocoagulation was performed if deemed necessary by the treating ophthalmologist. The paired t-test was used in the statistical analysis.

The study included 85 patients with Type 2 diabetes mellitus, aged 38 to 77 years (mean, 62.0 years). In the first examination, we found high-risk nonproliferative diabetic retinopathy in 68 eyes and proliferative diabetic retinopathy in 102 eyes. While IOP was significantly elevated in the first hour after PRP, it was not significantly different in the following measurements (Table 1). IOP over 30 mm Hg was seen in four eyes in the first hour after PRP, and these eyes were treated with timolol maleate 0.05% . IOP decreased to normal levels on the first day after PRP in all these eyes. While anterior chamber depth was significantly shallow in the first hour after PRP, it was not statistically different from the first day after PRP (Table 2). None of the eyes developed neovascular glaucoma or rubeosis iridis during the observation period.

Table 1. Intraocular pressure values (mm Hg).

Before PRP	After PRP				
	First hour	First day	First month	Third month	Sixth month
16.40±0.43	17.70±0.44*	16.57±0.32	16.02±0.47	16.30±0.40	16.61±0.37

*$P<0.05$ (paired t-test)

Table 2. Values of anterior chamber depth (mm).

Before PRP	After PRP	
	First hour	First day
3.06±0.04	2.99±0.04*	3.04±0.03

*$P<0.05$ (paired t-test)

Many investigators have reported a transient elevation during the first few hours after panretinal coagulation;[7-9] one reported a decrease within the first six months.[10] In this study, we detected an elevation of IOP following panretinal photocoagulation within a few hours. However, IOP was statistically different on the first day compared with the first, third or sixth month after PRP. Many transient changes after PRP occur only when a large area of the retina is treated in one session or in closely spaced sessions. These changes are due to the exudation of fluid from the choroids and retina. The exudation of fluid into the posterior segment causes a forward displacement of the lens-iris diaphragm. The forward movement of the iris-lens diaphragm often is associated with a rise in the intraocular pressure. The pressure probably rises because exudation of fluid into the posterior segment occurs faster than aqueous fluid can leave the anterior chamber through the trabecular meshwork, and the outflow facility usually is decreased. Another possible pathogenic mechanism is compression of episcleral veins by the flange of the fundus contact lens used in delivering the photocoagulation treatment.[7] Kaufman et al studied 1742 treated and untreated eyes, and IOP was measured during the first five years after PRP. They reported that their findings were not consistent with the suggestion that PRP might cause a meaningful long-term reduction in IOP. However, they found that neovascular glaucoma occurred more frequently among the untreated eyes. In our study, no difference was found on the first day, and in the first, third, and sixth months after PRP in IOP.

One of the major ophthalmic complications of diabetes mellitus is neovascular glaucoma. Several publications have suggested that PRP could cause the regression of rubeosis iridis and angle vascularization.[11-13] According to Wand et al.[11] PRP reduced or eliminated the stimulus for new vessel formation in the posterior pole and they showed that PRP in eyes with proliferative retinopathy decreased the incidence of rubeosis iridis, angle neovascularization, and probably neovascular glaucoma. In our cases, neovascular glaucoma did not develop. We think that PRP can take a preventive role against neovascular glaucoma. Whatever the cause, it appears that PRP reduces or eliminates the stimulus for new vessel formation in the posterior pole.

In this study, we detected anterior chamber depth shallowness in the first few hours after PRP. However, any differences were not detected on the first day of PRP. Mensher[14] had studied anterior chamber depth and angle changes after PRP for diabetic retinopathy. All patients treated with argon laser had shallowing of the anterior chamber and narrowing of the angle with angle closure in 31%. Blondeau[9] reported intraocular pressure increased in 17 of 18 eyes treated for diabetic retinopathy with argon laser PRP. All eyes had open anterior chamber angles before treatment and closed angles developed in three eyes. In our study, angle closure developed in one patient and it was treated with a cycloplegic agent. These studies show that anterior chamber angle closure may develop after PRP in open angle eyes as well. Angle closure glaucoma following PRP is believed to be caused by anterior rotation of the ciliary body secondary to a ciliochoroidal fluid and detachment. This is postulated as a result of transudation of fluid from the choroidal vasculature into the choroid and suprachoroidal space secondary to a thermally induced choroiditis and choroidal vascular occlusions.[15,16] According to Mensher,[14] anterior chamber shallowing after retinal photocoagulation is a vascular phenomenon, and the choroidal system is most likely affected. Hayreh and Baines have shown that anterior chamber shallowing can be produced acutely by an obstruction in the vortex venous system.[9,14] It has been demonstrated that choroidal vascular occlusions may occur after photocoagulation. It is possible that anterior fluid transudation may play a role in altering vitreous volume dynamics causing a shallowing of the anterior chamber. Risk factors for the development of the ciliochoroidal effusion after PRP include a greater number of laser applications, shorter axial length, and a greater percentage of retinal surface area treatment.[15]

In conclusion, a shallowing in the anterior chamber and elevation of IOP may occur in the first few hours after PRP, but treatment is hardly needed. However, patients with borderline IOP before PRP should be followed carefully for an elevation in first few hours after PRP.

Hakki Birinci
M. Rasih Abidinoglu
Ihsan Oge

Correspondence:
Hakki Birinci, MD
Department of Ophthalmology, Faculty of Medicine, Ondokuz Mayis University, Post Code 55139, Samsun, Turkey
Tel: +90-362-4576000 ext 2664
Fax: +90 362 4576041
habirinci@yahoo.com

References

1. Schiodte N. Ocular effects of panretinal photocoagulation. Acta Ophthalmol 1988;186:1-32.
2. Kanski JJ. Anterior segment complications of retinal photocoagulation. Am J Ophthalmol 1975;79:424-7.
3. Weiter JJ, Pflipsen KP. Retinal laser surgery: Principle and techniques. In: Schachat AP, Murphy RB. Editors. Retina. Mosby, 1994; Vol II, Chap 65:1051-60.
4. Gentile RC, Sidoti PA, Morinelli EN. Angle closure following panretinal photocoagulation: An ultrasound biomicrographic study. Ann Ophthalmol 1998; 30(1): 38-40.
5. Pavan PR, Rosanelli G, King DG, Weingeist TA. Complications of laser photocoagulation. In: Weingeist TA, Sneed SR. Editors. Laser Surgery in Ophthalmology. Appleton-Lange. 1992; Chapter 18:185-199.
6. Aiello LM. Diagnosis, management and treatment of nonproliferative diabetic retinopathy and macular edema. In: Albert DM, Jacobuec FA. Editors. Principles and Practice of Ophthalmology. W.B. Saunders Company 1994; Vol II, Chap 55:747-60.
7. Kaufman SC, Ferris III FL, Swartz M. Intraocular pressure following panretinal photocoagulation for diabetic retinopathy. Arch Ophthalmol 1987; 105(6): 807-9.
8. Liang JC, Huamonte FU. Reduction of immediate complications after panretinal photocoagulation. Retina 1984; 4(3): 166-70.
9. Blondeau P, Pavan PR, Phelps CD. Acute pressure elevation following panretinal photocoagulation. Arch Ophthalmol 1981; 99(7): 1239-41.
10. Schiodte SN, Scherfig E, Nissen OI. A pressure loweing effect of retinal xenon photocoagulation in normotensive diabetic eyes. Acta Ophthalmol 1980; 58(3): 369-76.
11. Wand M, Dueker DA, Aiello LM, Grant WM. Effects of panretinal photocoagulation on rubeosis iridis, angle neovascularization, and neovascular glaucoma. Am J Ophthalmol 1986; 332-339.
12. Vernon SA, Chang H. Panretinal cryotherapy in neovascular disease. Br J Ophthalmol 1988; 72(6): 401-5.
13. Caswell LF, Marks WP. Panretinal photocoagulation in the management of neovascular glaucoma. South Med J. 1988; 81(11): 1364-8.
14. Mensher J. Anterior chamber depth alteration after panretinal photocoagulation. Arch Ophthalmol. 1977; 95: 113-6.
15. Gentile RG, Stegman Z, Liebmann JM et al. Risk factors for ciliochoroidal effusion after panretinal photocoagulation. Ophthalmology 1986; 103:827-32.
16. Huamonte FU, Peyman G, Goldberg MF, Kocketz A. Immediate fundus complications after retinal scatter photocoagulation: clinical picture and pathogenesis. Ophthalmic Surg 1976; 7(1): 88-99.