

## Clinical Note

### Hypocalcemia resistant to 1,α hydroxyvitamin D treated successful with 1,25-dihydroxyvitamin D

Rula Goussous, MD, Ruba Barakat, MD,  
Nadim Jarrah, MD, Mohammed O. Abu-Hijleh, MD,  
Mohammed El-Zaheri, MD, Kamel Ajlouni, MD, Drmed.

We report a case of hypocalcemia caused by autoimmune hypoparathyroidism<sup>1</sup> which after 13 years of treatment with 1α-hydroxyvitamin D and calcium carbonate became resistant to treatment but it was finally corrected with 1,25-dihydroxyvitamin D. This is the 2nd case<sup>2</sup> reported in the literature.

A 17-year-old girl with autoimmune polyglandular syndrome type 1 (APS type 1) was first diagnosed with autoimmune hypoparathyroidism at the age of 4, and due to her older sister with APS type 1 (hypoparathyroidism, Addison's and premature ovarian failure), the diagnosis was made and she has been maintained on calcium (Ca) carbonate and 1α-hydroxyvitamin D ever since. The patient was 12-year-old, but one year later, she developed secondary amenorrhea and documented to be due to premature ovarian failure. She presented to our center at the age of 17 with numbness of fingers, toes and circumoral paraesthesia along with muscle spasms and twitching mainly affecting the facial muscles, and an element of laryngeal spasm. In addition, she complained of a 2-week history of watery diarrhea and severe throbbing headaches. Physical examination revealed positive Trousseau and Chvostek's signs with severe tetany and carpopedal spasm. Fundoscopy showed a bilateral papilledema with retinal hemorrhage in the right eye but with normal visual acuity and visual fields. Serum Ca level was 4.8 mg/dl (8.5-10.5mg/dl) and phosphate level was 6.5 mg/dl (2.4-4.5mg/dl). Plasma parathyroid hormone was 14.4pg/ml (13-45pg/ml), and the 24-hour urinary excretion of Ca was 1.5mg (normal up to 400mg/day). Serum creatinine, sodium, potassium, magnesium, alanine amino transferase, aspartate amino transferase, alkaline phosphatase and total bilirubin were all within the normal limits. Electrocardiogram showed prolonged corrected QT interval at 0.55 minutes per second. Stool analysis was also normal. The computerized tomography scan of the brain showed basal ganglia calcification. Lumbar puncture revealed increased intracranial pressure at 26 cm H<sub>2</sub>O. Upon admission, continuous intravenous infusions of Ca were given aside from Ca carbonate 2g every 6 hours and 1α-hydroxyvitamin D 1μg every 6 hours, of various batches, were used orally. Cerebrospinal fluid (CSF) tapping was carried out to decrease CSF pressure and she was started on acetazolamide. However, normalization of serum Ca level was not achieved. Gastrointestinal (GI) studies showed that no evidence of malabsorption. The patient continued to have high CSF pressure resulting to a decrease in visual acuity with new visual field defects.

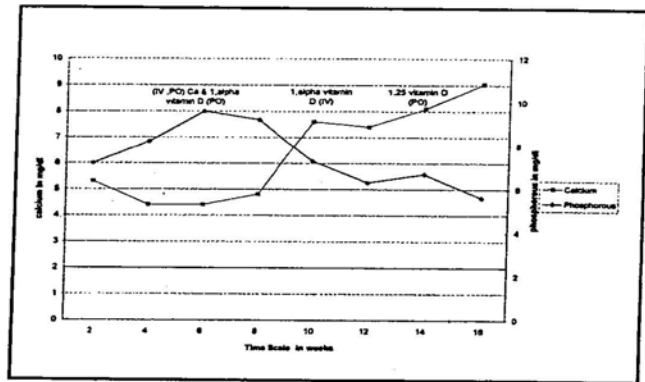


Figure 1 - Serum calcium and phosphorus levels in relation to therapy. IV - intravenous, PO - phosphorus, Ca - calcium

The serum was negative for antimitochondrial, anti-smooth-muscle, and antigliadin and antiparietal cell antibodies. Renal function and transaminases remained normal. Upper GI endoscopy showed non-specific gastritis, and the colonoscopy was normal with normal biopsies. Serum magnesium levels remained normal throughout the hospital stay. At this stage, the patient's condition stabilized, the CSF pressure decreased and her visual defects were corrected. The QT interval also normalized, and the intravenous Ca was discontinued. The Ca level stabilized at 6.4-7.2 mg/dl but it did not normalize. Malabsorption was still a theoretical possibility in the causation of this persistent hypocalcemia, intravenous 1α-hydroxyvitamin D infusions were given aside from the PO form and Ca carbonate. The serum Ca increased through the first few days but then decreased and could not be normalized. Vitamin D infusions were covered from sunlight, several batches were used, and it was made sure that they were not expired. We did not measure vitamin D metabolites. Figure 1 depicts serum Ca and phosphate levels in relation to therapy. Since there was such a poor response to treatment with Ca carbonate and 1α-hydroxyvitamin D, both IV and PO, a defect in 25-hydroxylation of vitamin D in the liver was suspected. To confirm this, oral treatment with 1,25-dihydroxyvitamin D in a dose of 0.25 mcg per day was initiated which normalized the serum Ca level and stabilized it. She was kept on 1,25-dihydroxyvitamin D with normal Ca levels and was discharged on 1,25-dihydroxyvitamin D (calcitriol) 0.25 mcg/d and Ca carbonate 500 mg, 6 tablets a day. Since then she has been well and her serum Ca level has been maintained between 8.4-10.0mg/dl. The patient described in this report has autoimmune hypoparathyroidism, which is a prominent component of APS type 1, with subsequent hypocalcemia that became resistant to therapy with 1α-hydroxyvitamin D but responded to 1,25-dihydroxyvitamin D. The efficacy of minute doses of this biologically active metabolite

indicates that its production may become impaired in certain patients with hypoparathyroidism.<sup>3</sup> There is only one reported case in the literature of a defective 25-vitamin D hydroxylation in the liver.<sup>3,4,5</sup>

In conclusion, the hypocalcemia in our patient became resistant to treatment with 1 $\alpha$ -hydroxyvitamin D, although she was reasonably well maintained on it for the preceding 13 years. Her hypocalcemia responded to treatment with 1,25-dihydroxyvitamin D and this makes a defective hydroxylation in the liver, although not definite, the most probable explanation. This possibility needs to be considered whenever a similar situation arises.

Received 20th July 2002. Accepted for publication in final form 16th November 2002.

From the National Center for Diabetes, Endocrinology and Genetics, Amman, Jordan. Address correspondence and reprint requests to Prof. Kamel Ajlouni, National Center for Diabetes, Endocrinology and Genetics, PO Box 13165, Amman 11942, Jordan. Tel. +962 (6) 5353376. Fax. +962 (6) 5353374. E-mail: ajlouni@ju.edu.jo

### References

1. Marx SJ. Medical progress: Hyperparathyroid and hypoparathyroid disorders. *N Engl J Med* 2000; 343: 1863-1875.
2. Kooh SW, Fraser D, DeLuca HF, Holick MF, Belsey RE, Clark MB et al. Treatment of hypoparathyroidism and pseudohypoparathyroidism with metabolites of vitamin D: Evidence for impaired conversion of 25-hydroxyvitamin D to 1 $\alpha$ , 25 dihydroxyvitamin D. *N Engl J Med* 1975; 293: 840-844.
3. Gustafsson J, Holmberg I, Hardell L, Foucard T. Hypoparathyroidism and liver disease-evidence for a vitamin D hydroxylation defect. A case report. *Acta Endocrinol (Copenh)* 1984; 105: 211-214.
4. Hogenauer C, Meyer RL, Netto GJ, Bell D, Little KH, Ferries L et al. Brief Report: Malabsorption due to cholecystokinin deficiency in a patient with autoimmune polyglandular syndrome type 1. *N Engl J Med* 2001; 344: 270-277.
5. Kind HP, Prader A, DeLuca HF, Gugler E. 1.25-Dihydroxycholecalciferol in hypoparathyroidism and pseudohypoparathyroidism. *Lancet* 1975; 7916: 1145-1146.

### Related Abstract Source: Saudi MedBase



Saudi MedBase CD-ROM contains all medical literature published in all medical journals in the Kingdom of Saudi Arabia. This is an electronic format with a massive database file containing useful medical facts that can be used for reference. Saudi Medbase is a prime selection of abstracts that are useful in clinical practice and in writing papers for publication.

#### Search Word: hypocalcemia

**Authors:** E. O. El-Amin, M. Khan  
**Institute:** Childrens Hospital, El-Madinah, Kingdom of Saudi Arabia  
**Title:** Hematological and biochemical findings in scorpion study children  
**Source:** Annals of Saudi Medicine 1991 November 6: 625-627

#### Abstract

Scorpion sting is a common pediatric problem in the region of El Madina El Munawara, Kingdom of Saudi Arabia. The prevalent species are *Leiurus quinquestriatus* and *Androctonus crassicauda*. The biochemical and hematological profiles of 96 children admitted to the hospital during one year with scorpion stings were analyzed. No hematological problem was encountered. In some patients hypocalcemia was encountered but no other biochemical disturbance was confirmed.